

# Tuberculous osteomyelitis in an immunocompetent patient with miliary tuberculosis

Gunawan,<sup>1</sup> A Harahap,<sup>2</sup> B Setiyohadi,<sup>3</sup> CM Rumende<sup>4</sup>

<sup>1</sup> Department of Internal Medicine, University of Indonesia School of Medicine/Cipto Mangunkusumo General Hospital, Jakarta;

<sup>2</sup> Department of Internal Medicine, Fatmawati Hospital, Jakarta;

<sup>3</sup> Division of Rheumatology, Department of Internal Medicine, University of Indonesia School of Medicine/Cipto Mangunkusumo General Hospital, Jakarta;

<sup>4</sup> Division of Pulmonology, Department of Internal Medicine, University of Indonesia School of Medicine/Cipto Mangunkusumo General Hospital, Jakarta

Osteomyelitis is an infection of the bone, which may be caused by direct pathogen inoculation following trauma of surgery, contiguous spread from adjacent soft tissue or joint, or hematogenous spread from a focus of infection. Hematogenous osteomyelitis accounts for 20% of all cases of osteomyelitis.<sup>1</sup> This type of osteomyelitis most often affect the long bones and vertebrae, although it could also affect other sites such as pelvic bones or clavicle.<sup>1</sup> *Mycobacterium tuberculosis* is one of the causes of hematogenous osteomyelitis, comprising of 10 to 35 percent of extrapulmonary tuberculosis, or 2% of all tuberculosis cases.<sup>2,3</sup> Joint involvement, when occur, is usually monoarticular, and mainly affect the weight-bearing joints such as hip or knee. Polyarticular cases occur in 10–15% of extrapulmonary tuberculosis cases in developing countries.<sup>4</sup> Tuberculous osteomyelitis cases are reported to be decreasing in number, probably because of earlier diagnosis and prompt management. In this article we report a case of tuberculous osteomyelitis in a patient with miliary tuberculosis.

## CASE REPORT

A 32-year-old male was admitted with complaint of 1-month history of worsening pain in the left ankle. The pain was intermittent and worsened by movement of the ankle. The pain was first experienced 4 months earlier after a trauma to the ankle when the patient was doing an exercise. At that time the ankle was swollen and the patient was unable to walk for 1 week. He then went to a traditional massage therapist. After the massage therapy he regained his ability to walk, although the ankle was still swollen and painful. The patient reported no redness or warmth on the ankle.

One month prior to the admission, the pain and swelling worsened. On the skin of the ankle there was now a wound with blood and purulent discharge. The patient went to a community health center (Puskesmas) and was given cefadroxil, amoxicillin, paracetamol, and piroxicam as medication, but he reported no improvement of his symptoms. Two weeks prior to the admission, the patient began having intermittent fever, followed with productive cough with yellow sputum which began one week later. The patient reported no night sweats, decrease in body weight, shortness of breath, or exercise

intolerance.

Physical examination at the time of admission revealed blood pressure of 110/80 mmHg, pulse rate of 88 beats/min, respiratory rate of 24 breaths/min, and normal body temperature. The patient appeared asthenic with body mass index of 17.6 kg/m<sup>2</sup>. On chest auscultation we found vesicular breath sound, which was decreased in intensity at the right fifth intercostal space, and coarse crackles over all lung field. There was no lymph node enlargement.

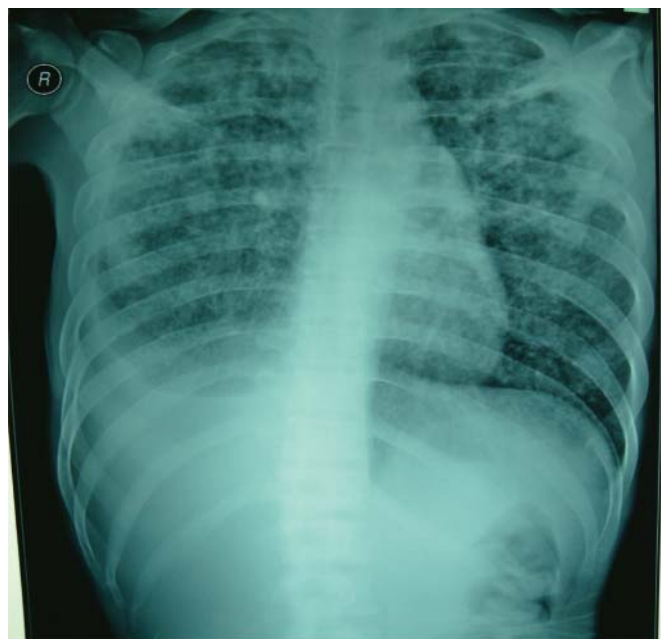On examination of the ankle we found that the skin around the left ankle was scaly and hyperpigmented. There were no signs of inflammation, but there was a 2.5-cm ulceration, which extended to the underlying connective tissue and muscle, on the medial malleolus. There was pain on palpation and movement of the ankle along with crepitation.

On laboratory examination we found that the patient had normochromic normocytic anemia with hemoglobin of 9 g/dL, normal leukocyte count, increased erythrocyte sedimentation rate, and positive C-reactive protein (table 1). On sputum examination twelve days after the admission we found positive acid-fast bacilli (+4 on three separate sputum collection). Pleural fluid analysis showed exudates with positive adenosine deaminase test. We also performed anti-human immunodeficiency virus test with enzyme-linked immunosorbent assay method, which showed negative result. Culture of the pus showed presence of *Pseudomonas aeruginosa*.

Chest radiograph showed miliary tuberculosis and right pleural effusion (figure 1). Radiographic examination of the left ankle showed signs of osteomyelitis with periosteal destruction of the tarsal bones (figure 2).

The patient was thus diagnosed with pulmonary tuberculosis and osteomyelitis of the left ankle bone, which was suspected as being the result of hematogenic spread of infection from the lung. He received an antituberculosis regimen consisting of rifampicin, isoniazid, ethambutol, and streptomycin (given as substitute for pyrazinamide due to the increased hepatic transaminases). In addition, the patient also received cefotaxime 1 g t.i.d for 14 days, but with no improvement of the left ankle infection. After the cefotaxime treatment, the patient underwent debridement of the left ankle and have a

biopsy specimen taken from the calcaneus. Histopathological examination showed caseation necrosis with surrounding lymphocytes and other chronic inflammatory cells (figure 3). The patient was then discharged and planned for regular evaluation in the outpatient clinic.

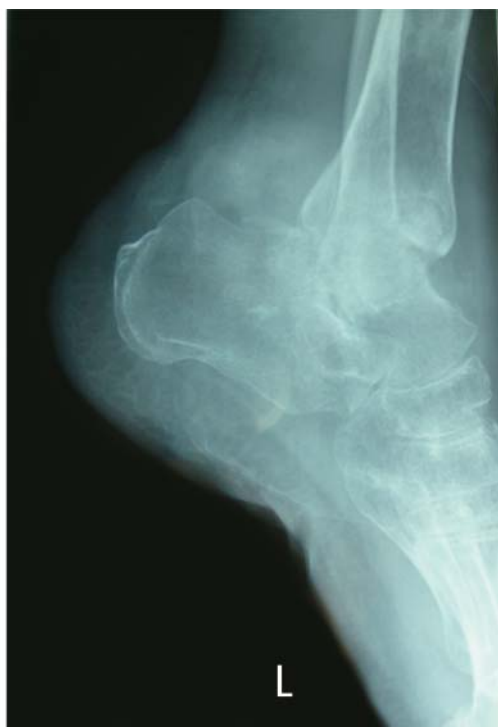
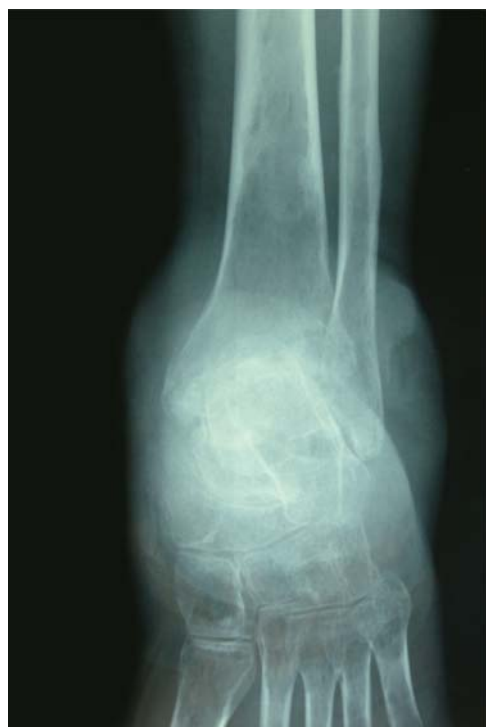
**Figure 1** Chest radiograph (postero-anterior view) showing miliary tuberculosis and right pleural effusion.

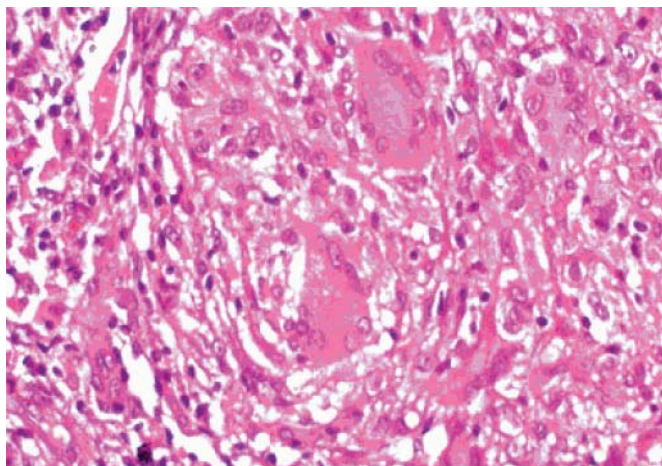
**Table 1** Laboratory results

	Result
Hemoglobin, g/dL	9.2
Hematocrit, %	29
Leukocyte count, $\times 10^3/\text{mm}^3$	5.3
Thrombocyte count, $\times 10^3/\text{mm}^3$	615
Mean corpuscular volume, fL	77.9
Mean corpuscular hemoglobin, pg	24.5
MCHC, g/dL	31.4
ESR, mm/hour	110
Aspartate aminotransferase, IU/L	111
Alanine aminotransferase, IU/L	79
Random blood glucose, mg/dL	102
Blood gas analysis	
pH	7.453
pCO <sub>2</sub> , mmHg	29.5
pO <sub>2</sub> , mmHg	75.8
HCO <sub>3</sub> <sup>-</sup> , mmol/L	20.2
O <sub>2</sub> saturation, %	96
Electrolyte, mmol/L	
Sodium	132
Potassium	4.15
Chloride	92
C-reactive protein (qualitative)	Positive
Anti-HIV (rapid)	Negative
Albumin, g/dL	3.3
Prothrombin time (control), sec	15.6 (13.2)
aPTT (control), sec	44 (37)
Fibrinogen	424
D-dimer	300

MCHC, mean corpuscular hemoglobin concentration; ESR, erythrocyte sedimentation rate; aPTT, activated partial thromboplastin time.



**Figure 2** Radiograph of the left ankle (antero-posterior (left) dan lateral view (right)) showing periosteal destruction of the calcaneus, talus, and parts of the proximal tibia with narrowing of the ankle joint space.



**Figure 3** Histopathological examination of a specimen taken from the calcaneus showing caseation necrosis surrounded by lymphocytes and chronic inflammatory cells. Original magnification 400  $\times$ .

## DISCUSSION

Tuberculosis cases in the developing countries often present with various organ involvement, with lymph node and pleural effusion as the most common extrapulmonary manifestations. Tuberculosis affecting bone and joint were found in 15–20% of all extrapulmonary tuberculosis.<sup>4</sup> Among cases of musculoskeletal tuberculosis, spine is the most commonly affected site (nearly 50% of all cases), followed with femur, tibia, fibula, and the joints.<sup>5</sup> Tuberculous osteomyelitis of the spine most often affect the thoracic and lumbar spine, which causes severe morbidity.<sup>6</sup> Tuberculous arthritis usually occur in weight-bearing joints such as hip or knee, and is usually localized to one joint; however, some multiarticular cases were found in 10–15% cases in developing countries.<sup>4</sup>

Extrapulmonary tuberculosis is more often found in patients with immunocompromised patients, or patients with malnourishment, advanced age or patients with kidney failure.<sup>7</sup> In immunocompromised patients, such as in patient with human immunodeficiency virus infection or acquired immunodeficiency syndrome, tuberculous osteomyelitis occur as a result of lymphogenous or hematogenous spread from a focus in the lung. We found no risk factors for immunodeficiency in our patient, and he was negative on the anti-HIV test; however, the fact that the patient had miliary tuberculosis rose a high suspicion that the osteomyelitis of the ankle occurred as a result of hematogenous spread of tuberculosis from the lung.

Tuberculous osteomyelitis has a low prevalence (1–3%); therefore, accurate and timely diagnosis often requires a high index of suspicion. Challenges in accurate diagnosis of this disease include inadequate knowledge and experience of the various manifestations of tuberculous osteomyelitis, and lack of consideration of this disease in the differential diagnoses.<sup>8</sup>

Clinical manifestations are often nonspecific and patients may present with pain, swelling, decrease in range of motion or

limitation of movement. Symptoms of tuberculosis infection may also present, such as decreased body weight, night sweats, malaise, and decreased appetite. Skeletal tuberculosis may go unnoticed for a long time until the adjacent structures such as skin, tissue, or joint are involved.<sup>5</sup>

Result of acid-fast smear examination often come negative, which causes delay in diagnosis. Besides, culture of the causative pathogen take a long time to grow.<sup>9,10</sup> Polymerase chain reaction technique or nucleic acid amplification test may help in making early diagnosis, but negative result do not exclude the possibility of tuberculosis.

Radiologic findings may include metaphyseal or epiphyseal destruction without sclerosis, periosteal reaction, and joint involvement.<sup>11</sup> Unlike pyogenic osteomyelitis, there is no disruption in articular margin and joint space. Solitary lytic lesion that may mimic neoplasia may be visible occasionally.<sup>11,12</sup>

Positive tuberculin test is an important clue in patients with tuberculosis, but negative result could be seen in 10% of patients. Although erythrocyte sedimentation rate may be elevated, it could be normal in some patients.<sup>13,14</sup> The gold standard for diagnosis is isolation of *M. tuberculosis* from culture of bone biopsy specimen. Histopathological examination of the specimen taken from the bone lesion that show caseation or specific chronic inflammation is also very important in making the diagnosis.<sup>15</sup>

Patients with tuberculous osteomyelitis are treated with antituberculosis therapy. First line agents consist of isoniazid (with vitamin B6 supplementation), rifampicin, ethambutol, and pyrazinamide. However, definitive therapy must be based on the result of susceptibility test of *M. tuberculosis*. Second line agents include aminoglycoside and quinolones.<sup>16</sup>

Duration of treatment may be varied from 6 to 12 months. Some patients may need additional 12 months or even more depending on clinical response. The Centers for Disease Control and Prevention recommends a regimen of 6–9 months (2 months of isoniazid, rifampicin, pyrazinamide, and ethambutol followed with 4–7 months of isoniazid and rifampicin) for extrapulmonary tuberculosis.<sup>16</sup> Surgery was not usually needed in the early stage of disease. Radical debridement is only intended for advanced stage or in cases when medication failed to provide improvement. Patients with significant involvement of joint may need arthrodesis or total arthroplasty.<sup>17</sup>

In summary, we have described a case of tuberculous osteomyelitis in a miliary tuberculosis patient. Hematogenous spread from a focus in the lung was suspected as the pathogenesis in this case. Because of the low prevalence, high index of suspicion in clinical and physical examination is needed in order to accurately diagnose tuberculous osteomyelitis. Several diagnostic tests are necessary in making the diagnosis, and the choice of one diagnostic test must be based on cost-effectiveness consideration in each case. Antibiotic regimen in tuberculous osteomyelitis is similar to pulmonary tuberculosis but with longer duration of treatment.

## REFERENCES

1. Lew DP, Waldvogel FA. Osteomyelitis. *Lancet* 2004;364:369–79.
2. Sharma SK, Mohan A. Extrapulmonary tuberculosis. *Indian J Med Res* 2004;120:316–53.
3. Peto HM, Pratt RH, Harrington TA, LoBlue PA, Armstrong LR. Epidemiology of extrapulmonary tuberculosis in the United States, 1993–2006. *Clin Infect Dis* 2009;49:1350–7.
4. Kumar K, Saxena MBL. Multifocal osteoarticular tuberculosis. *Int Orthop* 1988;12:135–8.
5. Vohra R, Kang HS, Dogra S, Sanggar RR, Sharma R. Tuberculous osteomyelitis. *J Bone Joint Surg Br* 1997; 79-B:562–6.
6. Weaver P, Lifeso RM. The radiological diagnosis of tuberculosis of the adult spine. *Skeletal Radiol* 1984;12:178–86.
7. Ellner JJ. Review: the immune response in human tuberculosis—implications for tuberculosis control. *J Infect Dis* 1997; 176:1351–9.
8. Walker GF. Failure of early recognition of skeletal tuberculosis. *Brit Med J* 1968;1:682–3.
9. Agarwal S, Caplivski D, Bottone EJ. Disseminated tuberculosis presenting with finger swelling in a Patient with tuberculous osteomyelitis: a case report. *Ann Clin Microbiol Antimicrob*. 2005;4:18. doi: 10.1186/1476-0711-4-18.
10. Glassroth J. In: *Tuberculosis. A Comprehensive International Approach*. Reichman LB, Hershfield ES, editor. New York, Marcel Dekker; 1993. Diagnosis of tuberculosis; pp. 149–165.
11. Abdelwahab IF, Bianchi S, Martinoli C, Klein M, Hermann G. Atypical extra spinal musculoskeletal tuberculosis in immunocompetent patients, a review. Part 1: Atypical osteoarticular tuberculosis and tuberculous osteomyelitis. *Can Assoc Radiol J* 2006;57:86–94.
12. Watts HG, Lifeso RM. Current concepts review: tuberculosis of bones and joints. *J Bone Joint Surg Am* 1996;78:288–98.
13. Tripathi AK, Gupta N, Khanna M, Ahmad R, Tripathi P. Tuberculosis presenting as osteolytic soft tissue swellings of skull in HIV positive patient: a case report. *Indian J Tuberc* 2007;54:193–5.
14. Fisk TL, Hon HM, Lennox IL. Detection of latent tuberculosis among HIV infected patients after initiation of highly active anti-retroviral therapy. *AIDS*. 2003;12:1102–4.
15. Vaughan KD. Extra spinal osteoarticular osteomyelitis: a forgotten entity? *West Indian Med J* 2005;54:202.
16. World Health Organization. *Treatment of tuberculosis: guidelines for national programmes*. 3rd edition. Geneva: World Health Organization; 2003.
17. Centers for Disease Control and Prevention. *Mycobacterium tuberculosis infection and disease*. *MMWR* 2009;58(RR-4):19–28.

## ERRATUM

In the previous edition, the volume and number of the edition, 'volume 3 number 1' should be 'volume 2 number 2.' We regret the error.